

# ABDOMINAL EXAM

---

Maria Giroux, HBSc, MD

# ABDOMINAL EXAM

## WITH ABDOMINAL EXAM, DO A PELVIC AND A RECTAL EXAM

- Vitals

### Inspection

- General inspection: pt is lying down comfortably, no obvious distress
- Skin- jaundice, scars, dilated veins, rashes, stretch marks
- Open mouth- dehydration
- Eyes- “look up”- scleral icterus, “look down”- pallor
- Hands- temperatue, cap refill <3sec, no clubbing
- Drape pt, bed flat, expose abdomen from pubic symphysis to xiphoid process

“I am going to look at your abdomen”

- Where did pain begin, where is it now?
- Flat, abdominal distension, scars from previous surgeries, bruises, Cullen’s and Grey Turner’s signs, visible organs or masses, bulging flanks (ascites)
- Umbilicus- location, shape, dilated veins, inflammation
- Bend down- peristalsis, aortic pulsations
- “Can you bring your head up and cough”- cough tenderness, hernias, masses

### Auscultation

“I am going to listen to your abdomen”

- BS (RLQ, 15sec)- presence, pitch, freq
- Bruits (15sec)- aorta, renal a., iliac a., femoral a.
- Rubbing sounds over liver and spleen
  - Liver- above R costal margin
  - Spleen- **Traube’s space** (6<sup>th</sup> rib, anterior axillary line, L costal margin)

### Important landmarks:

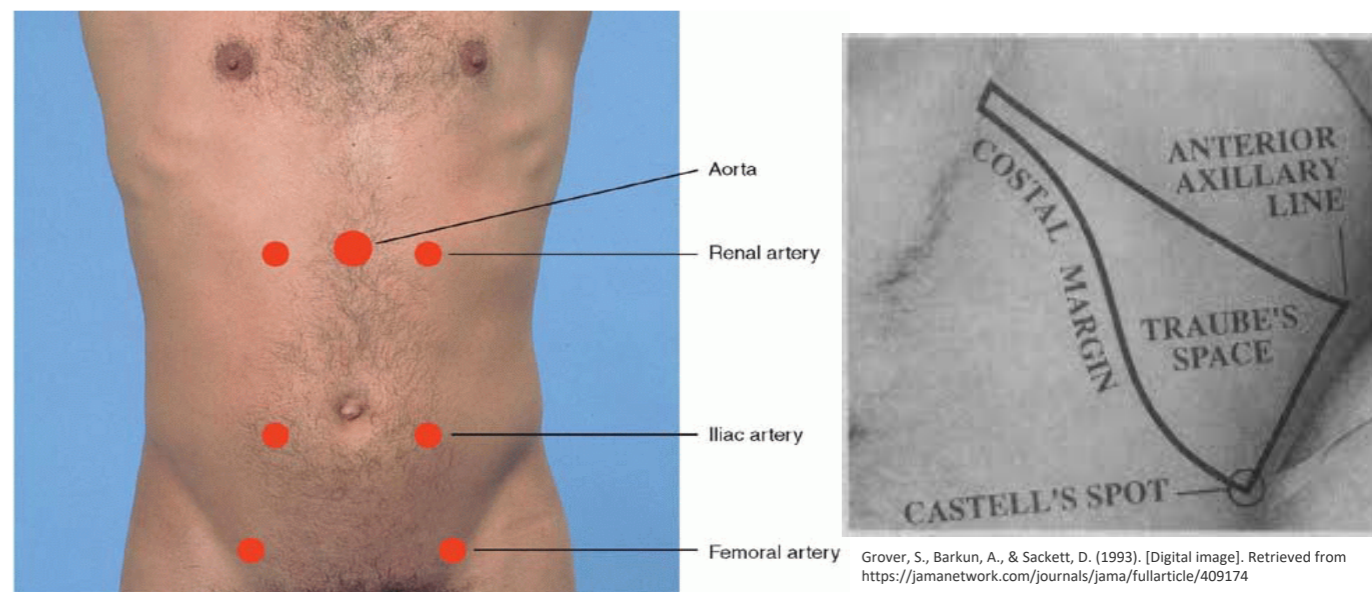
- Traube’s space: 6<sup>th</sup> rib, anterior axillary line, L costal margin
- Vertical liver span: 6-12cm from midclavicular line
- Liver’s edge: 3cm below R costal margin at midclavicular line
- Aortic width: <3cm
- McBurney’s point- 1/3 between umbilicus and ASIS

### Pelvic exam- looking for:

- Bleeding, vaginal discharge
- Adnexal masses, tenderness
- Cervical motion tenderness
- To obtain samples for C&S

### DRE- looking for:

- Bleeding, hemorrhoids, fissures, masses/nodules



Bickley, L. (2008). *Bates' Guide to Physical Examination and History-Taking* (10th ed.). Philadelphia, PA: Lippincott Williams and Wilkins.

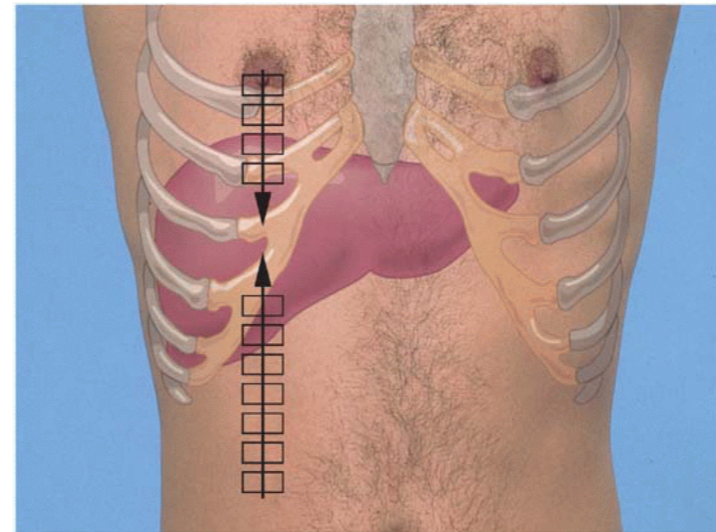
Grover, S., Barkun, A., & Sackett, D. (1993). [Digital image]. Retrieved from <https://jamanetwork.com/journals/jama/fullarticle/409174>

# ABDOMINAL EXAM

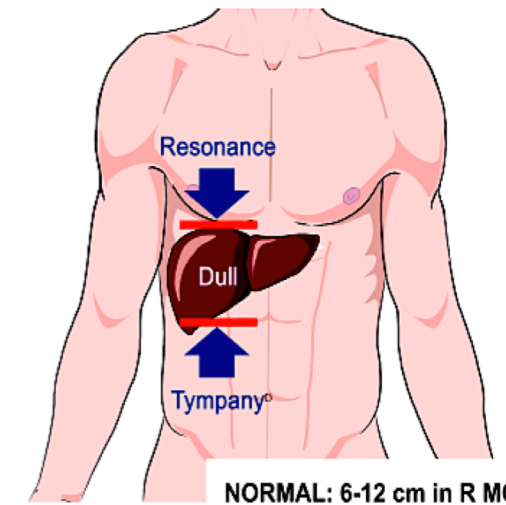
## Percussion

“ I am going to tap on your abdomen, please let me know if it hurts”

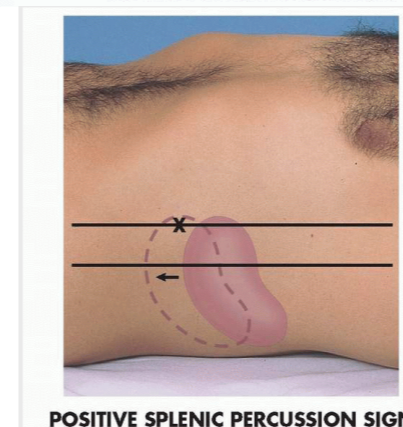
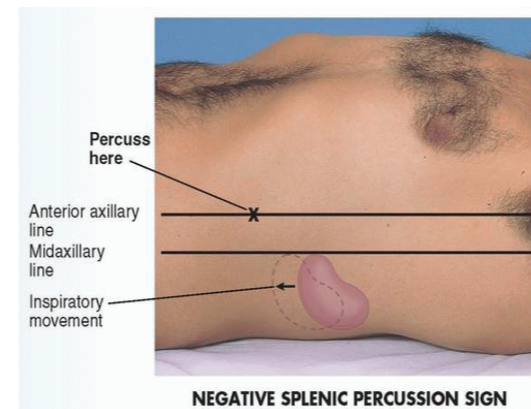
- 4 quadrants- tympany, dullness (N: tympanic with scattered dullness)
- Bladder- above pubic symphysis (dull)
- Gastric air bubble- below L costal margin (tympanic)
- Vertical liver span
  - N- midclavicular line: 6-12cm, midsternal line: 4-8cm
  - Lower border: start below bellybutton (tympany → dullness)
  - Upper border: start at nipple line (displace breast) (resonance → dullness)
- Spleen
  - Percuss in Traube’s space (N: tympanic)
  - Splenic percussion sign
    - Percuss in last interspace at anterior axillary line (N: tympanic) → “deep breath and hold,” percuss (N: remains tympanic)
- CVA (costovertebral angle)
  - Percuss between spinal column and 12<sup>th</sup> rib (tenderness)



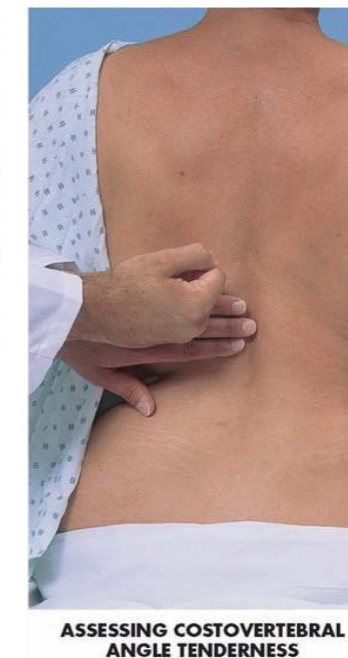Bickley, L. (2008). *Bates' Guide to Physical Examination and History-Taking* (10th ed.). Philadelphia, PA: Lippincott Williams and Wilkins.



[Digital image]. (n.d.). Retrieved from [http://fac.ksu.edu.sa/sites/default/files/module\\_7\\_abdomen\\_and\\_8\\_urinary.pdf](http://fac.ksu.edu.sa/sites/default/files/module_7_abdomen_and_8_urinary.pdf)



Bickley, L. (2008). *Bates' Guide to Physical Examination and History-Taking* (10th ed.). Philadelphia, PA: Lippincott Williams and Wilkins.



# ABDOMINAL EXAM

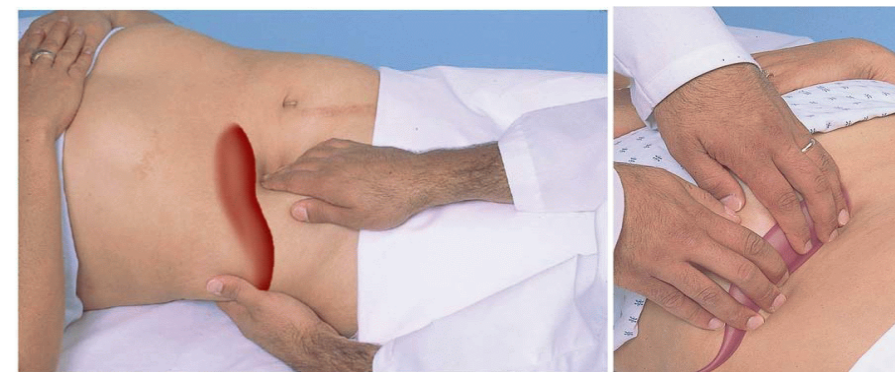
## Palpation

“I am going to feel your abdomen, let me know if it hurts”

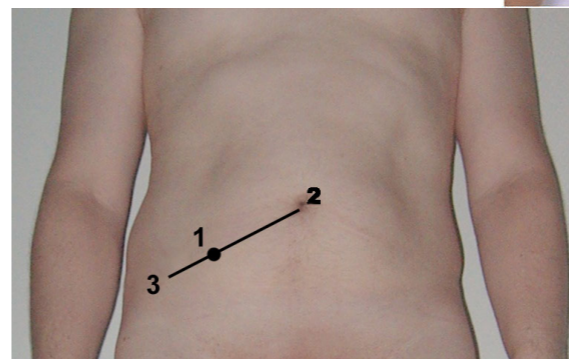
- Light (1 hand): 4 quadrants, start away from area of pain
  - Tenderness, rigidity, involuntary guarding, superficial organs and masses
- Deep (2 hands): 4 quadrants
  - Tenderness, masses, pulsations
- Rebound tenderness “does it hurt more when I press or let go?”
- McBurney’s point- pain, rebound tenderness
- Rovsing’s sign- rebound tenderness in LLQ
- Cutaneous hyperesthesia- pick up skin between thumb and index finger (pain)
- Liver
  - L hand under 11-12<sup>th</sup> ribs, push up; R hand lateral to rectus muscle at midclavicular line, start below lower border of liver dullness, press in and up; move hand upwards to costal margin
  - Location (N: 3cm below R costal margin at midclavicular line, soft, smooth, slightly tender, no masses)
- Murphy’s sign
  - Hook fingers in R hand under costal margin where lateral muscle intersects costal margin, “breathe,” tenderness in cholecystitis
- Spleen
  - L hand under L ribs, elevate pt 45 degrees, R hand below L costal margin, press in, “breathe,” move towards costal margin
  - Palpable, location, tenderness (N: not palpable)
  - Turn pt towards me, repeat
- Aorta
  - 1 hand on each side of aorta (L of midline in upper abdomen)
  - N aortic width: <3cm
- Bladder
  - Above pubic symphysis → tenderness

## Peritoneal signs:

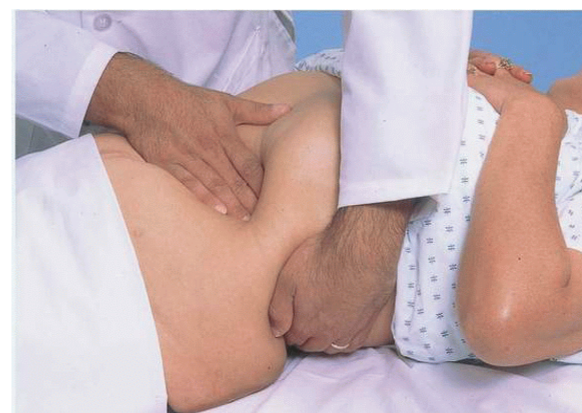- Involuntary guarding
- Rigidity
- Rebound tenderness



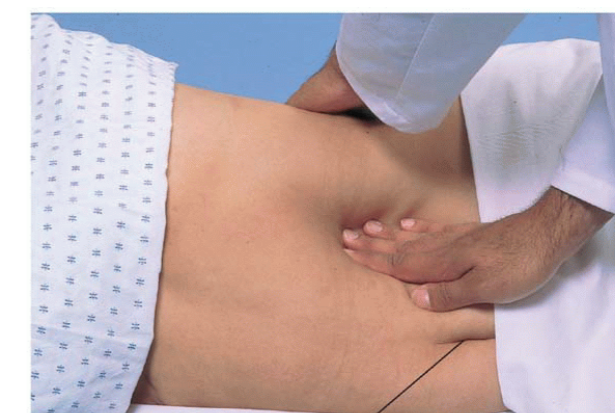Bickley, L. (2008). *Bates' Guide to Physical Examination and History-Taking* (10th ed.). Philadelphia, PA: Lippincott Williams and Wilkins.



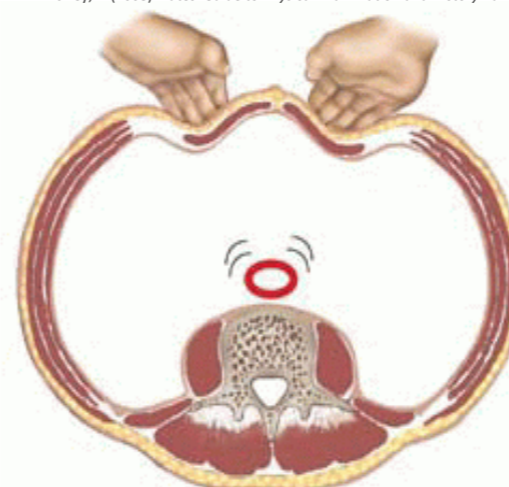[Digital image]. (n.d.). Retrieved from [https://en.wikipedia.org/wiki/McBurney's\\_point](https://en.wikipedia.org/wiki/McBurney's_point)



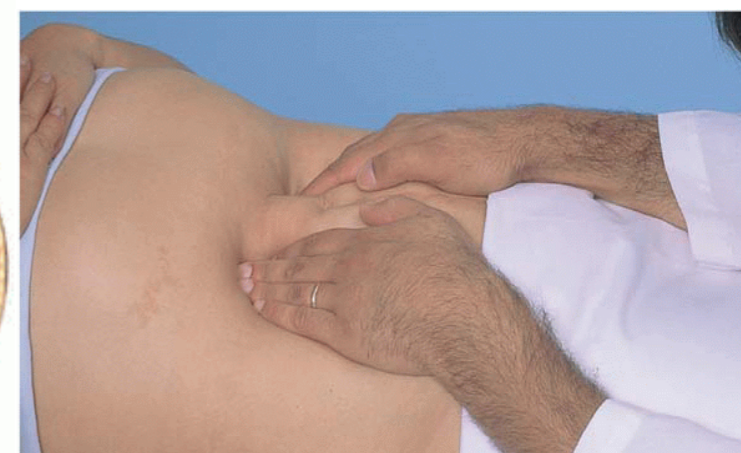Bickley, L. (2008). *Bates' Guide to Physical Examination and History-Taking* (10th ed.). Philadelphia, PA: Lippincott Williams and Wilkins.



Umbilicus

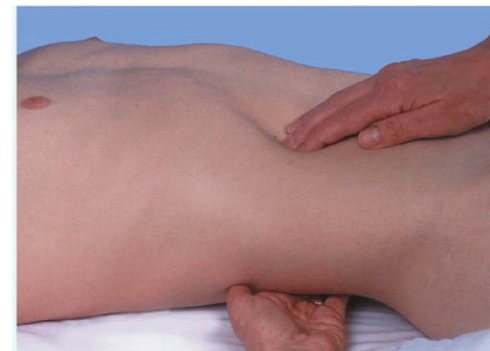

Bickley, L. (2008). *Bates' Guide to Physical Examination and History-Taking* (10th ed.). Philadelphia, PA: Lippincott Williams and Wilkins.



# ABDOMINAL EXAM

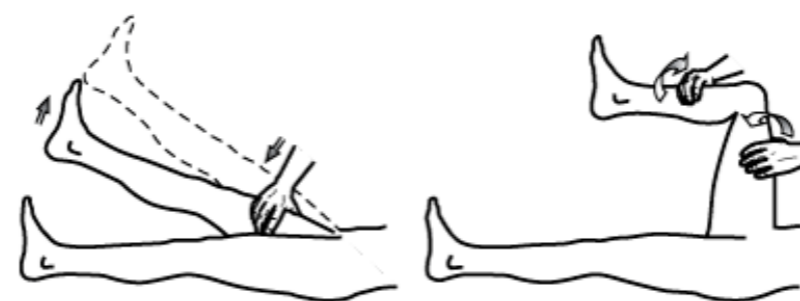
- Kidneys
  - Size, contour, tenderness (N: R palpable in thin well relaxed women, L not palpable)
  - R kidney- L hand under 12<sup>th</sup> rib, push up, “deep breathe,” press R hand into RUQ (trying to capture kidney between 2 hands, “breathe out and hold,” release R hand)
  - L kidney- L hand reach over pt, lift L flank, R hand press into LUQ (trying to capture kidney between 2 hands, “breathe out and hold,” release R hand)
- Inguinal lymph nodes



Bickley, L. (2008). *Bates' Guide to Physical Examination and History-Taking* (10th ed.). Philadelphia, PA: Lippincott Williams and Wilkins.

## COVER PT'S ABDOMEN

- Psoas sign- hand above knee, raise thigh against hand (increased abdo pain)
- Obturator sign- internally rotate hip (RLQ pain)



A. Iliopsoas test

B. Obturator test

[Digital image]. (n.d.). Retrieved from <https://accessmedicine.mhmedical.com/ViewLarge.aspx?figid=40503287&gbosContainerID=null&gbosid=null>

## Appendicitis:

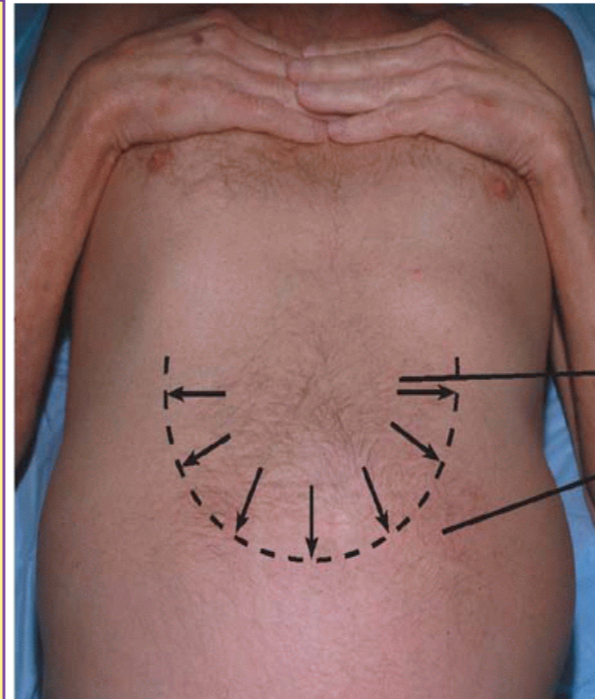
- Where did pain begin (umbilicus), where is it now (RLQ)
- Cough (pain worse)
- Palpation:
  - Involuntary guarding, muscle rigidity
  - McBurney's point- pain, rebound tenderness
    - 1/3 between umbilicus and ASIS
  - Rovsing's sign- rebound tenderness in LLQ
  - Cutaneous hyperesthesia- pick up skin between thumb and index finger (pain)
- Psoas sign- hand above knee, raise thigh against hand (increased abdo pain)
- Obturator sign- internally rotate hip (RLQ pain)

## Crohn disease:

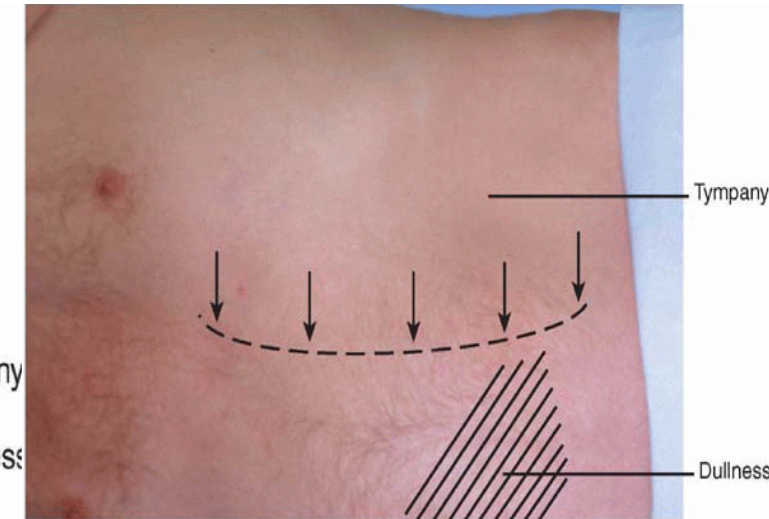
- Inspection:
  - truncal obesity, moon-like face, red eyes
  - Mouth ulcers
  - Hands- nail changes, clubbing, skin rash, psoriatic changes, joint tenderness
  - Abdomen: scars, striae
  - Lower limbs: erythema nodosum
  - DRE: fissures, fistula
- Palpation: SI joints for sacroilitis

## Ascites

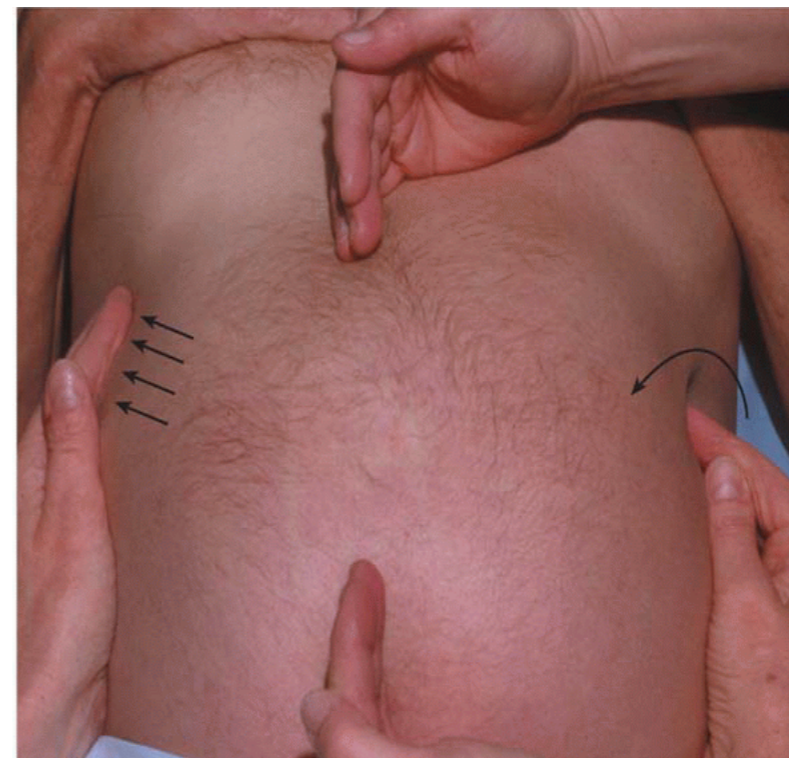- Inspection: protuberant abdomen, bulging flanks
- Shifting dullness
  - Percuss in the centre (tympany) outwards (dullness), mark border when tympany → dullness
  - Turn pt to 1 side, repeat, mark borders
  - N: borders are the same
  - Ascites: dullness shifts downwards
- Fluid wave test
  - 1 person presses on the edges of abdomen at midline
  - Tap 1 flank with fingertip, feel for impulse transmitted to other side (N: no transmission)



Bickley, L. (2008). *Bates' Guide to Physical Examination and History-Taking* (10th ed.). Philadelphia, PA: Lippincott Williams and Wilkins.



Bickley, L. (2008). *Bates' Guide to Physical Examination and History-Taking* (10th ed.). Philadelphia, PA: Lippincott Williams and Wilkins.



Bickley, L. (2008). *Bates' Guide to Physical Examination and History-Taking* (10th ed.). Philadelphia, PA: Lippincott Williams and Wilkins.

# Reference

---

Bickley, L. (2008). *Bates' Guide to Physical Examination and History-Taking* (10th ed.). Philadelphia, PA: Lippincott Williams and Wilkins.